

## Sinus Imaging

Sinusitis is a common problem, thought to affect up to 15% of adults. Acute sinusitis is defined as a paranasal sinus infection lasting less than 3 weeks whereas subacute infection lasts 3 weeks to 3 months. Often medical management including antibiotics, steroids and decongestants is the first line of treatment. Imaging studies are often requested at some stage, to determine the presence and extent of inflammatory disease and to evaluate sinus anatomy.

Patterns of sinusitis may relate to occlusion of drainage pathways or the development of nasal polyps. Colonisation by fungi such as aspergillus can be identified and occasionally symptoms may be on the basis of uncommon entities such as inverting papilloma or a sinus tumour. Normal variants of sinus anatomy can also be assessed as these may predispose to sinus or nasal occlusion during an acute episode.

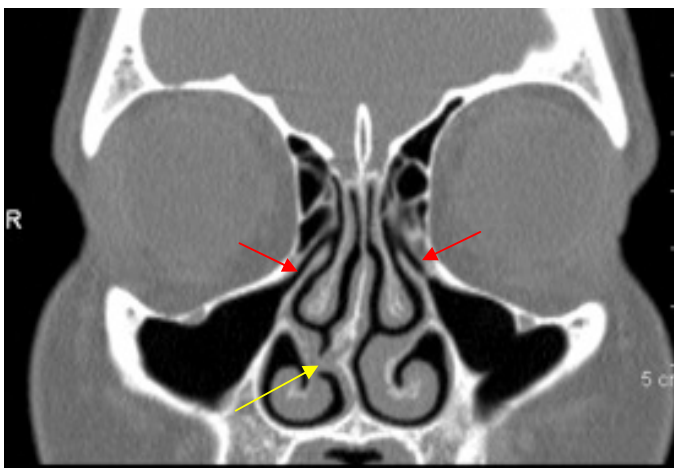
It is generally recommended that imaging only take place after at least 4-6 weeks of medical therapy and should be delayed in patients with acute upper respiratory tract infections.

Sinus CT has been shown to be superior to plain films for evaluation of the paranasal sinuses. In the era of single slice CT technology, only a limited number of direct coronal scans were obtained through the sinuses – the so-called 'mini-series'. Direct coronal scanning requires the patient to lie on their abdomen with the neck extended and is relatively uncomfortable. A direct coronal 'full-series' of up to 25 images was only performed in certain circumstances.

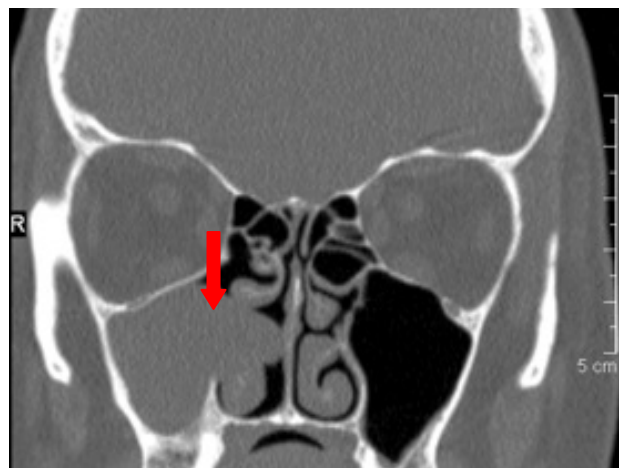
Now, with the advent of multi-detector helical scanners it is possible to obtain very thin axial images with the patient supine, and to then reconstruct these in both coronal and sagittal planes. This not only increases patient comfort but also limits artefact from dental amalgam as well as giving exquisite anatomical detail. This imaging can then act as a useful roadmap if referral for surgical management is to be considered.

Sinus CT imaging is available at our rooms in Remuera and Glenfield

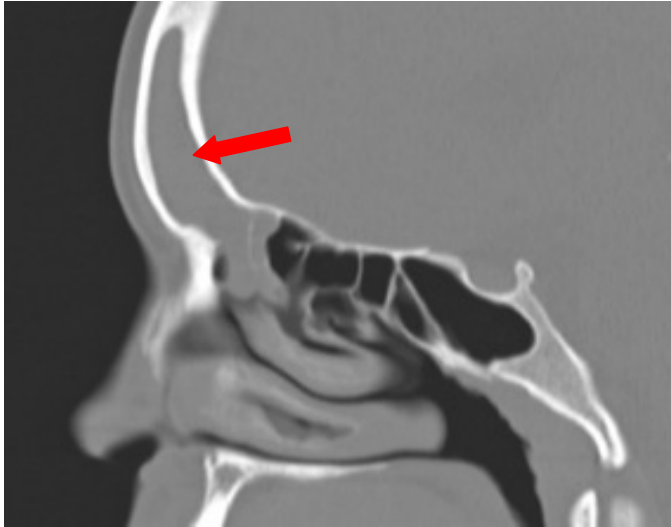
**Kate O'Connor**



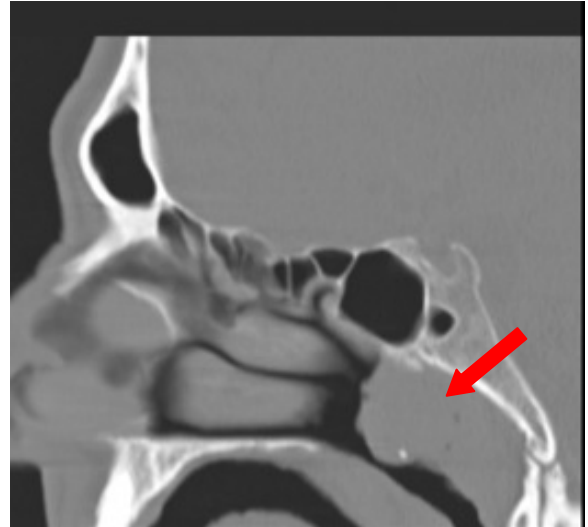**Fig 1.** Normal ostiomeatal units. A coronal reconstruction clearly shows the anatomy of the ostiomeatal units (red arrows). A septal spur can also be seen on this image (yellow arrow).



**Fig 2.** Antrochoanal polyp. A large polyp arises from the right maxillary antrum and protrudes into the nasal airway (arrow).



**Fig 3.** Frontal sinusitis. A sagittal reconstruction shows opacification of the frontal sinus (arrow).



**Fig 4.** Nasopharyngeal mass. Lymphoma involving the adenoids (arrow).

## Introducing Barnaby Clark, Brigid Connor and David Perry...



**Barnaby Clark** graduated from the Auckland University School of Medicine in 1999 and trained in radiology in Auckland. He was a fellow in MRI at Middlemore Hospital in 2006 and worked with the Auckland University Bone Research Group, with published research papers. He was the ARG musculoskeletal fellow in 2007, then spent two years furthering his experience in musculoskeletal imaging, MRI and imaging guided procedures in Brisbane. He has returned to permanent positions at ARG and North Shore Hospital.



**Brigid Connor** is an Otago graduate (1996). She trained in radiology in Auckland and subsequently spent a year as a consultant at Middlemore Hospital. She gained overseas experience in the UK before returning to Auckland, where she is completing a fellowship in interventional radiology at Auckland Hospital. She is an associate of the Auckland Radiology Group. Brigid has wide general interests and considerable experience in a number of subspecialty areas.



**David Perry** graduated from Auckland Medical School in 1996 then trained in radiology in Auckland, with a fellowship at Starship Children's Hospital in 2004. David has been working at Starship Radiology and National Women's Ultrasound since 2005. His main areas of hospital practice are paediatric and perinatal imaging, high risk pregnancies and congenital abnormalities. His modality interests include obstetric and paediatric ultrasound and MRI, with particular interest in paediatric neuroimaging and fetal MRI. David is an associate of the Auckland Radiology Group.